

ZOOM IN: AMED INSIGHTS

January 2026



Randolph Shoup, DDS, FAGD, MAMED **AMED Annual Meeting Chair**

AMED is planning a revolutionary meeting. Your AMED leadership, under the guidance of Dr. Juan Carlos Ortiz Hugues, will present a world symposium on high levels of magnification and the cutting-edge advancements in biomimetic dentistry.

This world symposium will present ALL forms of magnification, not solely microscopes. The speakers are hand picked from around the world presenting the most advanced and cutting-edge research and clinical practices in biomimetic restorative dentistry.

There will be two days of lectures that will bring the participating dentists from the most basic science of adhesive dentistry and bonding to the most advanced and complex direct composite rehabilitation and full mouth restoration with indirect ceramic.

The Academy of Microscope Enhanced Dentistry

ANNUAL SESSION

25th Annual Dental Microscopy Meeting & Scientific Session

November 6-8, 2026

Waikiki Beach Marriott Resort & Spa

For More Information

microscopedentistry.com

(813)444-1011





Every restorative dentist absolutely must attend this world symposium. Participants will never have the opportunity to experience the level of excellence in scientific dental research and clinical practice presented in one location.

In addition to the two days of lectures there will be hands-on workshops presented. They include advanced anterior composite restorations, full mouth rehabilitation with both direct and indirect restorative materials, ergonomics for the dental practitioner for your health, your back, and your career, the restoration of the endodontically treated tooth, and advanced techniques to maximize the bond to tooth structure.

As always AMED will offer certification testing for certification as an AMED Certified Microscope Dentist.

This is a meeting that is a “MUST ATTEND” for all dentists.

More details will be coming but for now register for the meeting and make your hotel accommodation.

On behalf of the entire AMED leadership, I am looking forward to seeing you there.

Best Regards,
Dr. Randy Shoup
Annual Meeting Chair





Christopher A. Laing, DDS
AMED Secretary



Dear Colleagues & Friends,

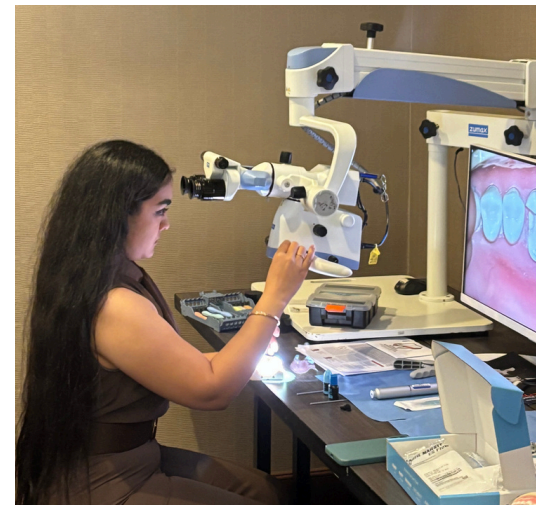Reflecting on our past year, I'd like to thank all of you for supporting AMED's efforts to bring high magnification dentistry to the world. The forward momentum we experienced together was a collective achievement. Thank you, to all the academy members, the board, our speakers and contributors, and our executive director and his staff in continuing to support AMED.

As we welcome all that 2026 has in store, let me also encourage you to continue looking to AMED to help you make the most of your endeavors. This year we continue to strive to bring some of the world's most clinically precise minds together, to share what they have to learn on their journeys for more predictable, lasting, conservative and profitable dentistry, all through the precision afforded by high magnification.

Lastly, don't delay marking your calendars with this year's annual session in beautiful Hawaii. Bring your family, an open mind this year November 6-8, 2026. Please visit our website <https://microscopedentistry.com/lookout> for emails with registration promotions.

Sincerely,

Christopher Laing, DDS
Secretary, AMED 2025-2026



2026 AMED Webinars

Register Now at MicroscopeDentistry.com!



Microscope Enhanced Dental Surgery

Understand how microscope-enhanced dental surgery and advanced technologies improve precision, broaden procedures, and enhance outcomes for patients and practitioners.

January 27, 2026 7PM EST

Presented By: Dr. Shepard DeLong

Magnification in Aesthetic Dentistry

Discover how magnification and the dental microscope enhance precision, improve clinical decision-making, and support minimally invasive aesthetic dentistry.

February 21, 2026 10AM EST

Presented By: Dr. Rafael Piñeiro Sande



From Microscope to System: Building a Microscope-Ready Practice

Discover how a microscope-first setup makes magnification a daily default, boosting ergonomics, control, and patient perception.

March 12, 2026 7PM EST

Presented By: Dr. Cosimo Pilolli



Cracked Teeth: What Can We Predictably Save?

Understand how to detect, diagnose, and manage cracked teeth using advanced imaging and clinical techniques for more predictable outcomes.

March 26, 2026 8PM EST

Presented By: Dr. Judy D. McIntyre



Techniques for Discovery of the MB2 Canal

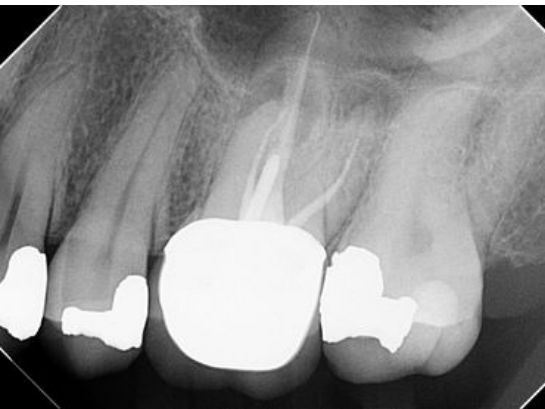
Mark Dreyer, DMD, PA

Dr. Mark Dreyer is a general dentist whose practice is limited to endodontics, with a career spanning nearly four decades. A 1986 graduate of the University of Florida College of Dentistry, Dr. Dreyer practiced as a general dentist until 2000, when he transitioned to a referral-based endodontic practice. Since then, he has completed more than 25,000 endodontic procedures, all performed using the dental operating microscope. He is a founding member of the International Academy of Endodontics and maintains active membership in the American Dental Association, Florida Dental Association, Central District Dental Association, and the Dental Society of Greater Orlando. Dr. Dreyer currently practices in Winter Garden, Florida. Learn more at www.drmarkdreyer.com.



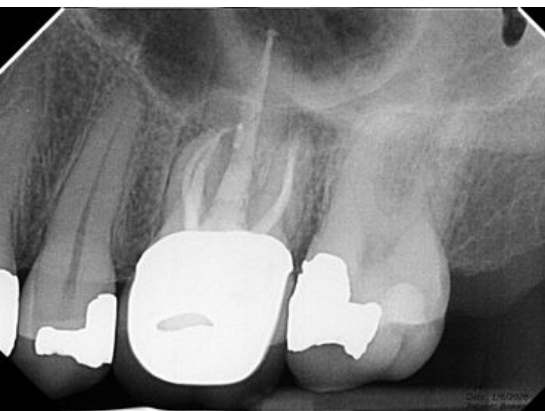
The elusive mesiobuccal second canal (MB2) is a small, frequently missed canal located in the mesiobuccal root of maxillary molars. While notoriously difficult to locate, its discovery is critical for successful root canal treatment. Failure to identify and treat this canal often leads to endodontic failure and the need for retreatment, resulting in additional cost and inconvenience for the patient.

Research has demonstrated that the MB2 canal is present in a high percentage of maxillary first molars and in a slightly lower, yet still significant, percentage of maxillary second molars. This article outlines practical tactics that can be used to locate this elusive canal.



Prevalence of the MB2 Canal

The most frequently cited classic study is that of Dr. John Stropko, who reported identification of the MB2 canal in 93% of maxillary first molars and up to 60% of maxillary second molars.¹ Since then, numerous studies have been published with varying reported rates of occurrence.^{2,3,4}



The author trained under Dr. Stropko, among other clinically astute, microscope-proficient endodontists, and has found that Dr. Stropko's reported 93% incidence closely mirrors his own clinical experience. Having limited his practice to endodontics since the year 2000, the author routinely encounters MB2 canals at a similar frequency.

Clinical Reference & Case Example

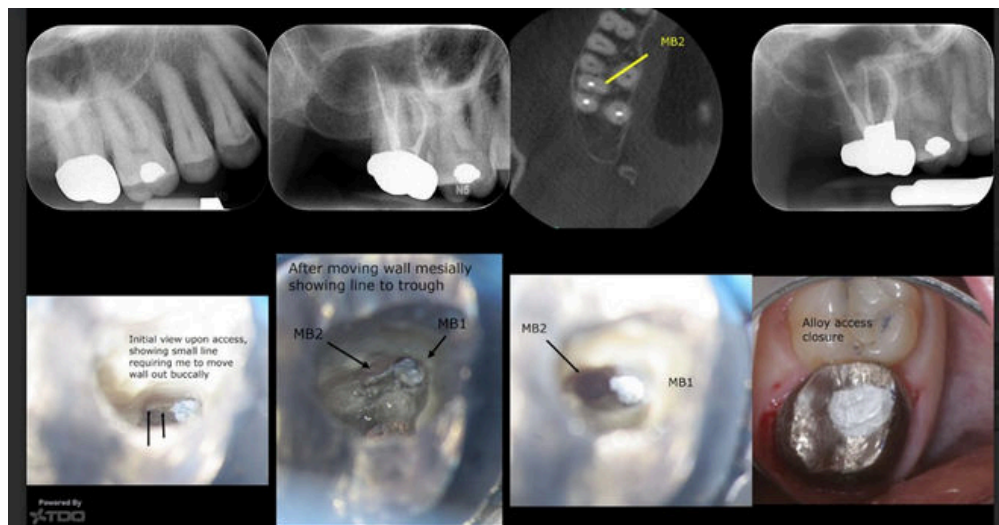
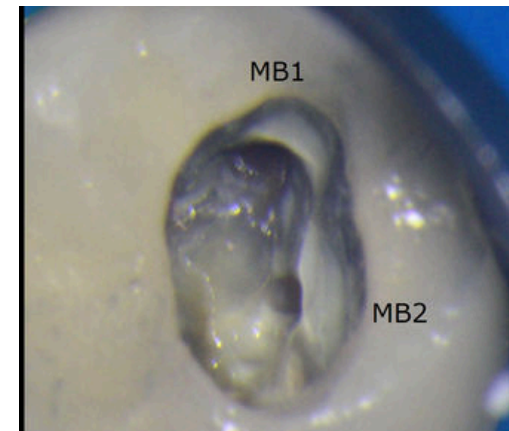
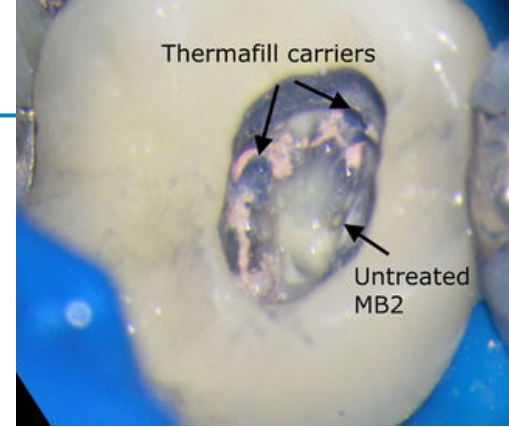
For the microscope-proficient dentist, retreatment of maxillary molars due to missed MB2 canals is a common feature of daily practice. The following case was completed only this week in the author's office. In this case, the previously untreated MB2 canal was identified and treated while the other three canal systems were retreated.

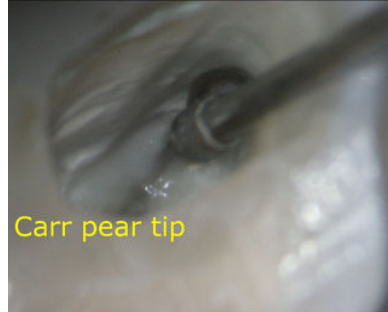Upon removal of the prior core material and post, the untreated MB2 canal was readily evident, and no further expansion of the original access preparation was necessary. However, the author has found that in many cases, the initial access preparation must be judiciously expanded to uncover the MB2 orifice.

In this case presentation, a faint line extending in a palatal direction from the MB1 canal could be visualized. Initially, the MB2 canal was not located, so the other three canals were obturated and a progress CBCT scan was obtained. The CBCT axial image confirmed an off-centered position of the MB1 canal, indicating the presence of an MB2 canal. Additional apical troughing was then performed, ultimately resulting in successful discovery of the MB2 canal.

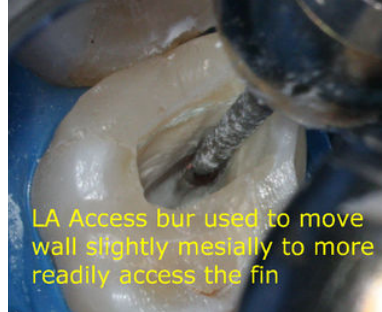Identifying the MB2 Location

In nearly all maxillary first molars—and to a lesser extent, second molars—a line extending from the MB1 canal can be observed. This line may lead to a distinct MB2 orifice or, in some cases, represent a fin without a separate canal. Often, this line is subtle or not immediately evident, requiring careful removal of dentin from the mesial chamber wall to expose it.





Carr pear tip



LA Access bur used to move wall slightly mesially to more readily access the fin



In the case illustrated, the initial photograph showed a faint suggestion of this line. The mesial wall was carefully moved further mesially, fully exposing the line and allowing direct access to the MB2 canal orifice.

Instrumentation & Techniques

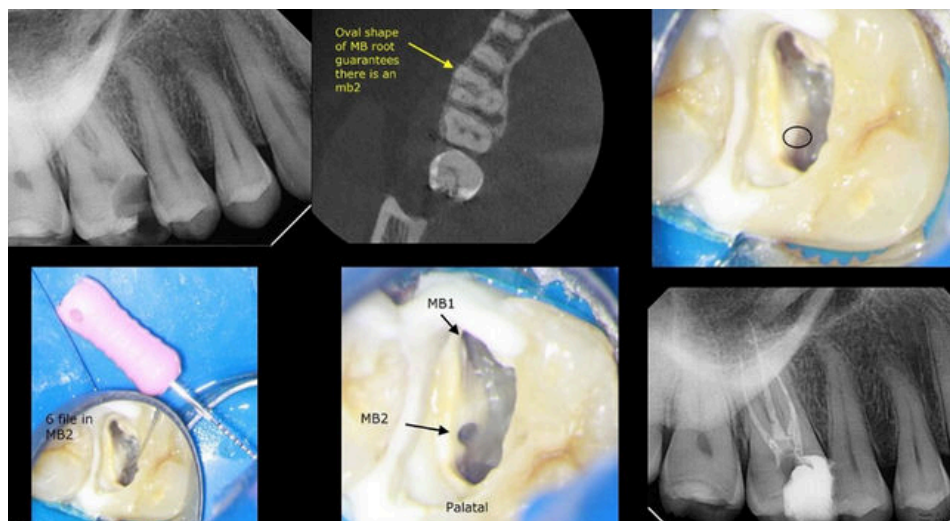
The tools used by the author to move the mesial wall and uncover this line include high-speed tapered diamond burs and ultrasonic (U/S) tips. While the high-speed diamond is efficient, it should only be used by experienced clinicians working under the operating microscope, as excessive dentin removal can occur if caution is not exercised.

An equally effective and often safer approach is the use of ultrasonic tips. Both techniques allow controlled mesial wall relocation and, when necessary, apical troughing to locate the MB2 orifice. The Carr pear tip referenced in this article can be sourced from www.eie2.com.

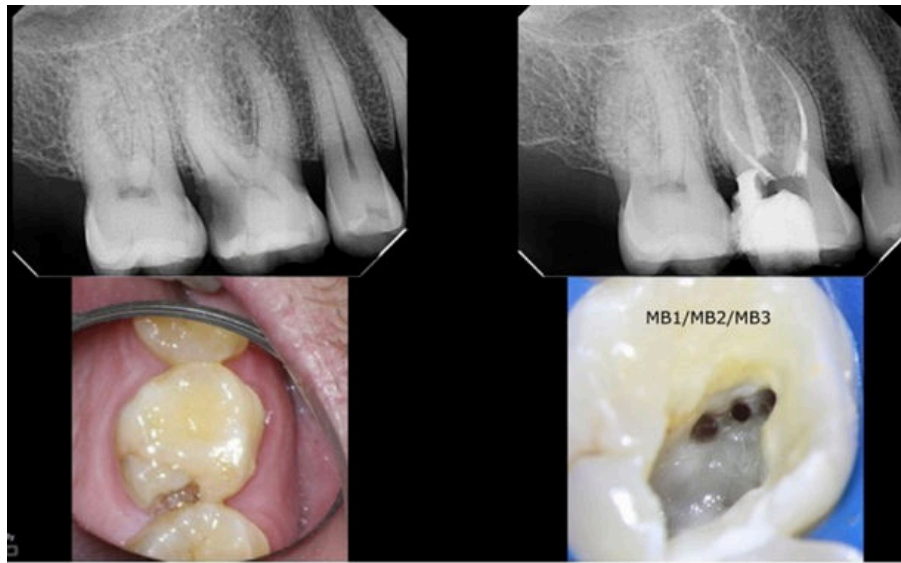
Role of CBCT Imaging

Careful evaluation of CBCT axial slices can greatly aid the clinical search for the MB2 canal. In rare cases, the MB2 orifice may be located closer to the palatal canal than to the MB1 canal. A clue to this unusual anatomy can be identified by an increased buccal-to-palatal dimension seen on axial CBCT images. The case shown below demonstrates such a presentation.

On occasion, when the MB1 and MB2 canals are separated by a significant distance, a Vertucci Type VIII configuration may be present, with three distinct canal orifices in the mesiobuccal root. Although uncommon, this anatomical variation will be encountered periodically by the careful and experienced clinician.



MB2 Canal



Conclusion

Clinicians proficient in the use of the operating microscope are uniquely positioned to deliver the highest quality care to their patients. While this is true across many areas of dentistry, it is particularly critical in endodontics, where visualization directly impacts treatment outcomes.

The author has mentored younger general dentists and endodontists in the techniques required to locate elusive MB2 canals. This training has included co-observation through the microscope and hands-on practice using extracted teeth and the instrumentation described in this article.

It is the author's hope that this article provides practical benefit to clinicians seeking to improve their endodontic outcomes through more consistent identification and treatment of the elusive MB2 canal.

References

1. Stropko JJ. *Canal morphology of maxillary molars: clinical observations of canal configurations.* Journal of Endodontics. 1999;25(6):446-450. doi:10.1016/S0099-2399(99)80276-3.
2. Martins JNR, Alkawas MAM, Altaki Z, et al. *Worldwide analyses of maxillary first molar second mesiobuccal prevalence: a multicenter cone-beam computed tomographic study.* J Endod. 2018;44(11):1641-1649.e1. doi:10.1016/j.joen.2018.07.027
3. Hiebert BM, Abramovitch K, Rice D, Torabinejad M. *Prevalence of second mesiobuccal canals in maxillary first molars detected using cone-beam computed tomography, direct occlusal access, and coronal plane grinding.* J Endod. 2017;43(10):1711-1715. doi:10.1016/j.joen.2017.05.011.
4. Blank-Gonçalves LM, da Silva EJM L, do Carmo Chagas Nascimento M, Limoeiro AG, Manhães-Jr LRC. *Anatomical configuration of the MB2 canal using high-resolution cone-beam computed tomography.* J Endod. 2025;51(5):609-615. doi:10.1016/j.joen.2025.01.006.

2026 AMED Courses

Register Now at [MicroscopeDentistry.com!](https://MicroscopeDentistry.com)

Dental Microscope User Guidelines Course: Virtual

The Postural, Positioning, and Ergonomics Applied Systematic Approach to the Effective and Proper Use of the Dental Microscope

Virtual

3 Hrs. 9:00 am - 12:00 pm EST

Presented By: Dr. Juan Carlos Ortiz Hugues

Full Mouth Rehab & Restorative Under the Microscope

Unlock the full potential of microscopic dentistry and elevate your skills in prosthodontics and restorative dentistry with our comprehensive seminar

Charlotte, NC

Jan 30-31 | June 5-6 | Oct 23-24

Presented By: Dr. Juan Carlos Ortiz Hugues & Dr. William Linger

Endodontics Under the Microscope

High quality & efficient endodontics using the dental microscope for endodontists and general dentists

Charlotte, NC

Jan 30-31 | June 5-6 | Oct 23-24

Presented By: Dr. Juan Carlos Ortiz Hugues & Dr. William Linger

AMEED

MEET THE BOARD



Dr. Juan Carlos Ortiz Hugues
President



Dr. Randolph Shoup
Immediate Past
President



Dr. Osvaldo Mayoral
Vice President



Dr. William Linger
Treasurer



Dr. Christopher Laing
Secretary



Dr. Mark Limosani
Members at Large



Dr. Kiarash Karimi
Members at Large



Dr. Tony Wu
CE Chair

Don't Forget to Renew Your Membership!

The benefits of being an AMED Member include:

- Certified Microscope User
- AMED Fellowship (FAMED)
- Mastership Awards (MAMED)
- Complimentary Webinars & CE
- and More!

Go to microscopedentistry.org to renew today!

Thank You

to our 2026 sponsors



THE LEADER IN HIGH
MAGNIFICATION DENTISTRY