

# ZOOM IN: AMED INSIGHTS

December 2024

Dr. Jorge F. Zapata, ed

## Advancements in Adhesive Dentistry: Deep Subgingival Restoration and the Dental Microscope

### Case Presentation

---

A patient presented with sensitivity in the upper left quadrant, particularly to cold stimuli. X-rays revealed deep subgingival decay under an existing resin filling at the distal aspect of tooth #13. A thermal test was normal, and the diagnosis was reversible pulpitis.

### Clinical Procedure

1. Anesthesia and Rubber Dam Placement: After anesthetizing the patient, a rubber dam was placed to isolate the tooth and control moisture. (Figure #1)
2. Decay Removal: The old filling was removed using a 330 carbide bur at 12x magnification. Surgical latch round burs (#2 and #4) were then used to remove all soft dentin and decay up to the gingival level, without touching the interproximal papilla. (Figure #2)
3. Gingivectomy: The interproximal papilla was carefully removed (gingivectomy) using electrosurgery.
4. Decay Removal Confirmation: A caries indicator was applied to

ensure all decay was removed. The remaining decay was thoroughly eliminated.

5. Biofilm Removal: A prophy jet was used to clean any biofilm remaining on the tooth surface.
6. Bleeding Control: If bleeding occurred during the procedure, a hemostatic agent was applied.
7. Matrix Placement: A sectional matrix was selected with a height of 6–7 mm to accommodate the depth of the restoration. The matrix may need to be customized at the buccal or lingual sides for optimal adaptation. A wedge was placed with Teflon tape to secure the matrix, followed by the placement of a composite ring (Figure #3).
8. Etching and Bonding: Blue etch was applied selectively to the enamel surface according to the manufacturer's instructions. IDS and RCT were then applied to protect and isolate the pulp from external stimuli. The bonding agent of choice was Clear fill SE from Kuraray, known for its antibacterial properties (MDPB), (Figure #4)
9. Incremental Composite Placement: Composite resin was placed in 2–4 mm increments starting at the gingival floor. Each layer was carefully cured before the next increment was placed. This approach helps reduce the resin's stress and allows for better control of the C-factor (the ratio of bonded to unbonded surfaces).
10. Curing: The matrix wings were opened to improve light access for curing from the buccal, lingual, and occlusal surfaces. After curing, the matrix was removed, and any remaining composite was cured as needed.
11. Finishing: The final restoration was adjusted, and the surface was polished for optimal esthetics and function (Figure #5).

# Case Presentation - Figures

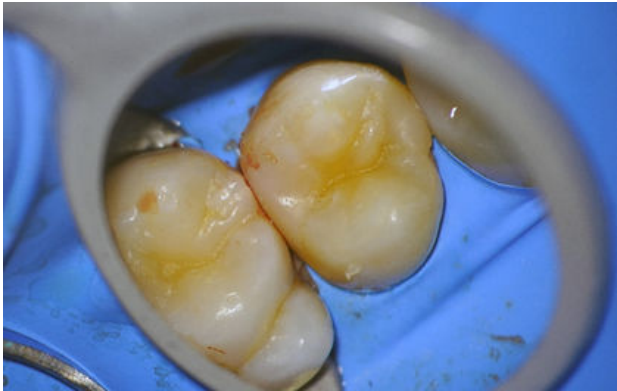

Figure 1

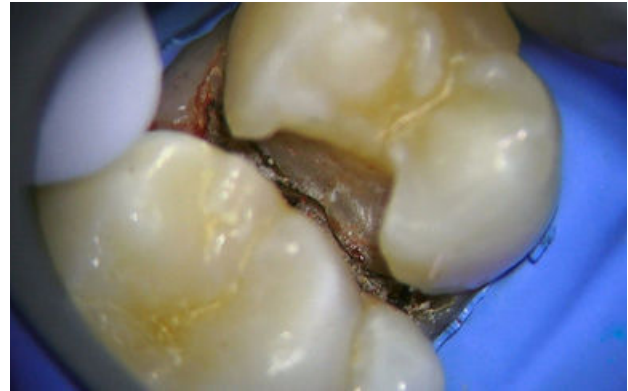

Figure 2




Figure 3

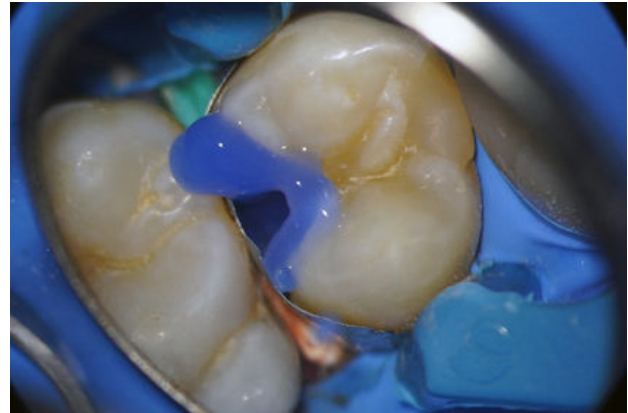

Figure 4

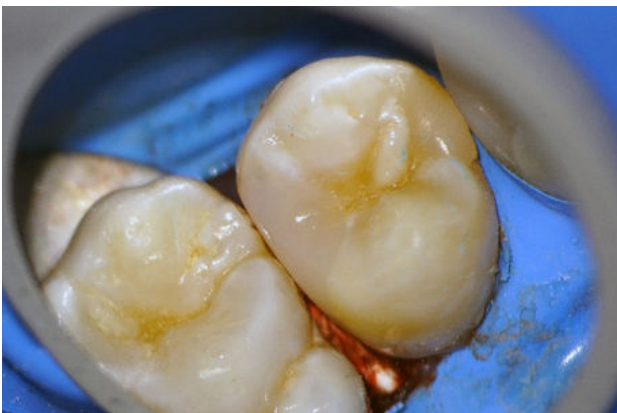

Figure 5